

CASE REPORT

Open Access

Unusual case of severe arrhythmia developed after acute intoxication with tosylchloramide

Vincenzo Lariccia^{1†}, Alessandra Moraca^{2†}, Marco Marini², Annamaria Assunta Nasti¹, Ilaria Battistoni², Salvatore Amoroso^{1*} and Gian Piero Perna²

Abstract

Background: Drugs not commonly considered to be cardioactive agents may cause prolongation of the QT interval with resultant torsades de pointes and ventricular fibrillation. This form of drug toxicity often causes cardiac arrest or sudden death.

Case presentation: After accidental ingestion of tosylchloramide a caucasian 77-year-old woman, with a family history of cardiovascular disease and hypertension, was admitted to the intensive care unit following episodes of torsades de pointes with a prolonged QT/QTc interval (640/542 ms). The patient received an implantable cardioverter-defibrillator, was discharged from the hospital with normal QT/QTc interval and did not experience additional ventricular arrhythmias during one year of follow-up.

Conclusion: This is the first report concerning an unusual case of torsades de pointes after accidental intoxication by ingestion of tosylchloramide. The pronounced impact of the oxidizing agent tosylchloramide on the activity of some of the ion channels regulating the QT interval was identified as a probable cause of the arrhythmia.

Keywords: Tosylchloramide, Acute intoxication, Arrhythmia, Ventricular fibrillation, Ion channels

Background

Because of its high activity against fungi and bacteria, tosylchloramide is a widely used disinfectant agent for common applications such household cleaning and swimming pool disinfection. Many case reports describing tosylchloramide intoxication have been already published in the past showing that the chronic exposure to this compound may cause hypersensitivity reactions, such as asthma [1,2], conjunctivitis [3], whereas toxic pneumonitis [4], cardiovascular collapse and myocardial damage may occur in acutely intoxicated patients [5]. Here we report the first case of a severe arrhythmia developed in the context of acute oral intoxication with tosylchloramide.

Case presentation

A 77-year-old woman presenting shoulder girdle pain was admitted to our hospital with suspected coronary

syndrome. She had a history of hypertension; treated since 5 years with Perindopril (5 mg once daily) and a family history of cardiovascular disease. Few hours after the admission at the Emergency Room (ER) the patient experienced a cardiac arrest due to a "Torsade de Pointes" (TdP) degenerated into ventricular fibrillation which required DC shock (200 J), as documented by electrocardiogram (ECG) (Figure 1). After specific questioning for drug intake, the patient revealed She had accidentally (non-intentionally) ingested an entire sachet of Euclorina (containing 2.5 g of tosylchloramide) between 5 and 6 hours before TdP.

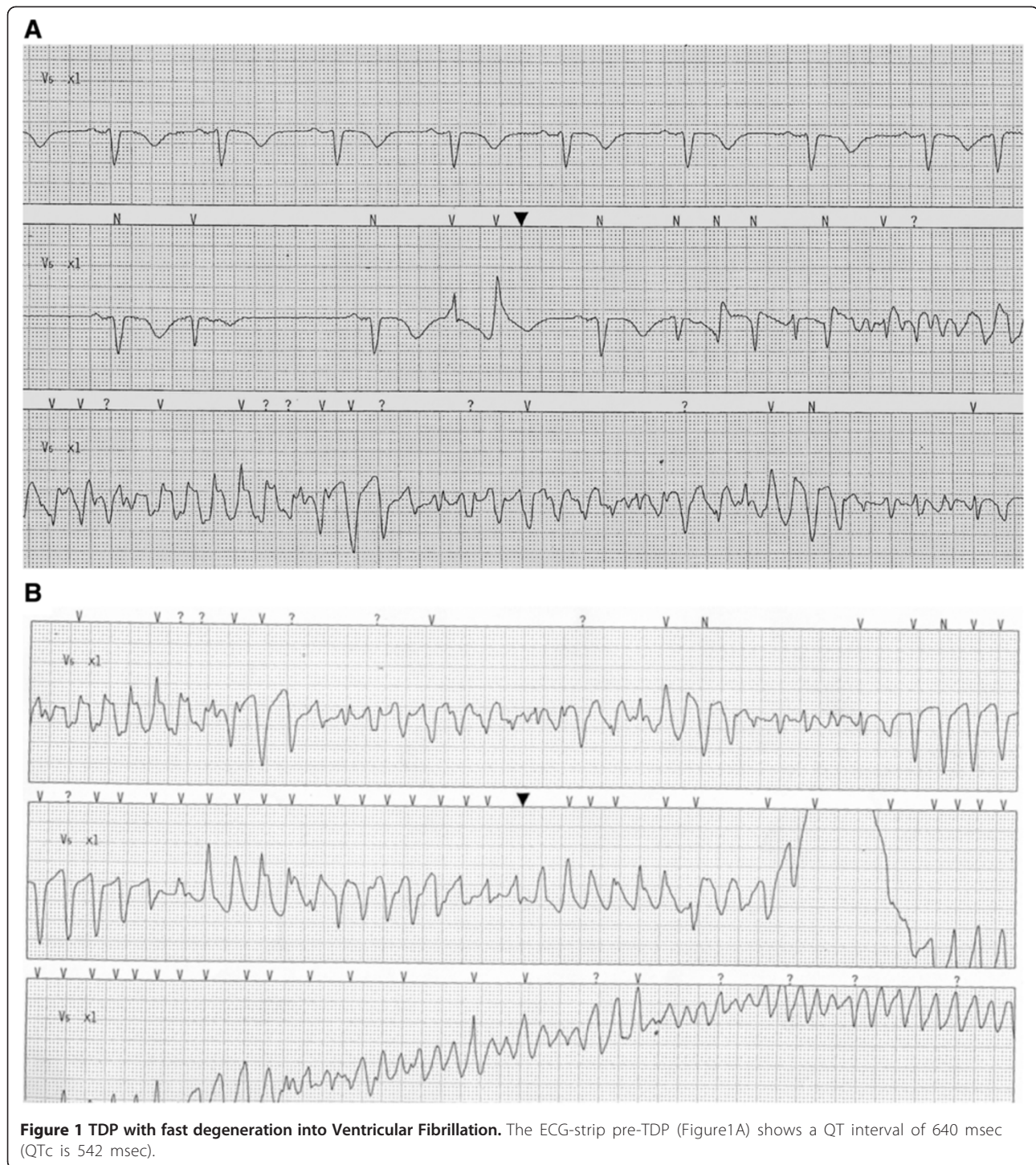
Surface ECG on admission in ER showed sinus rhythm with pre-existing left bundle branch block (LBBB). Serum potassium was in slightly lower normal range (3.3 mEq/l, before 3.8 mEq/l), while other haematological parameters were in their respective reference intervals (data not shown). On admission to the cardiology Intensive Care Unit (ICU) the ECG disclosed sinus bradycardia (55 bpm) with significant alteration in the QT interval (QT/QTc = 640/543 msec; Figure 2) that was significantly prolonged over a 24-hour period. Thereafter the patient underwent an echocardiography

* Correspondence: s.amoroso@univpm.it

†Equal contributors

¹Department of "Biomedical Sciences and Public Health, University "Politecnica delle Marche", Ancona, Italy

Full list of author information is available at the end of the article



that revealed concentric left ventricle hypertrophy with a mild reduction in global systolic function (LVEF = 50%) due to LBBB-induced dyssynergy of the interventricular anterior septum wall.

The middle left anterior descending coronary artery (LAD) had a non-significant stenosis (< 50%) as revealed

by coronary angiography and IVUS control (Figure 3). A not significant stenosis was detected in a non-dominant right coronary artery (Figure 3). According to the criteria defined in Thygesen et al. [6], myocardial infarction was excluded for the following reasons: a) no symptoms or electrocardiographic changes were detected; b) the peak

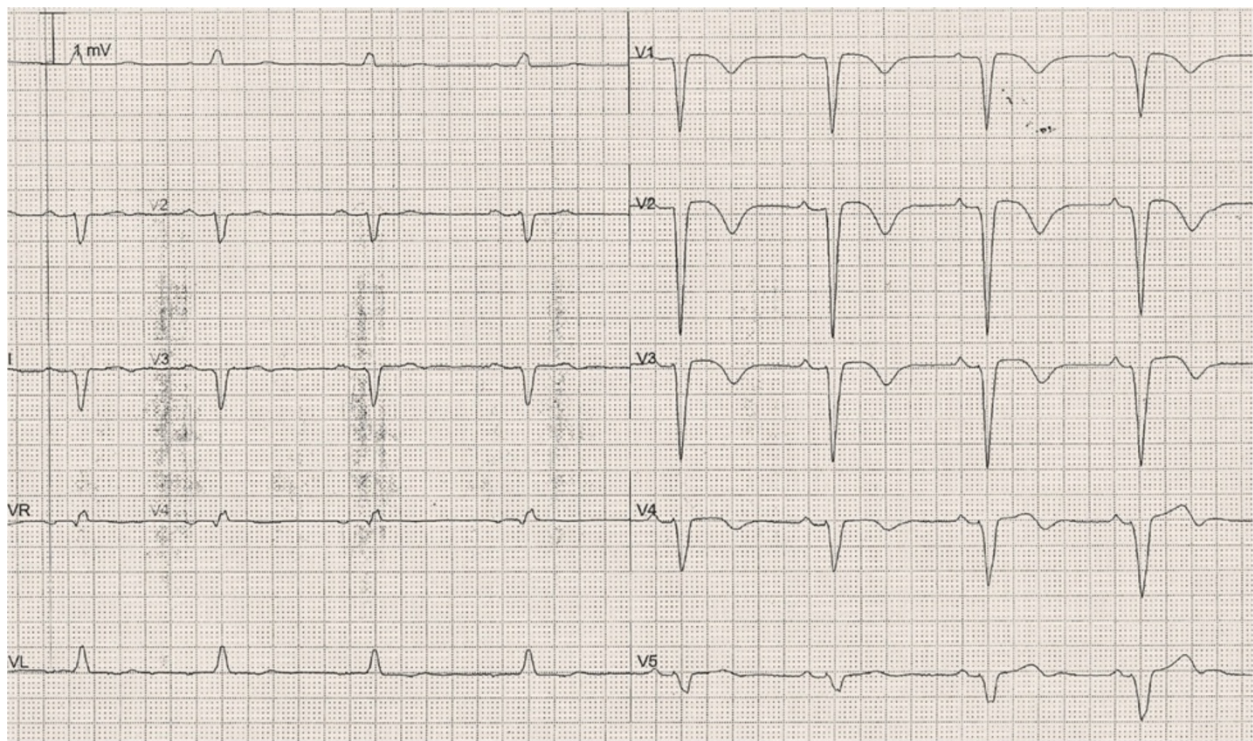


Figure 2 ECG at the admission to ICU shows a LBBB with a prolonged QT/QTc interval (640–542 msec).

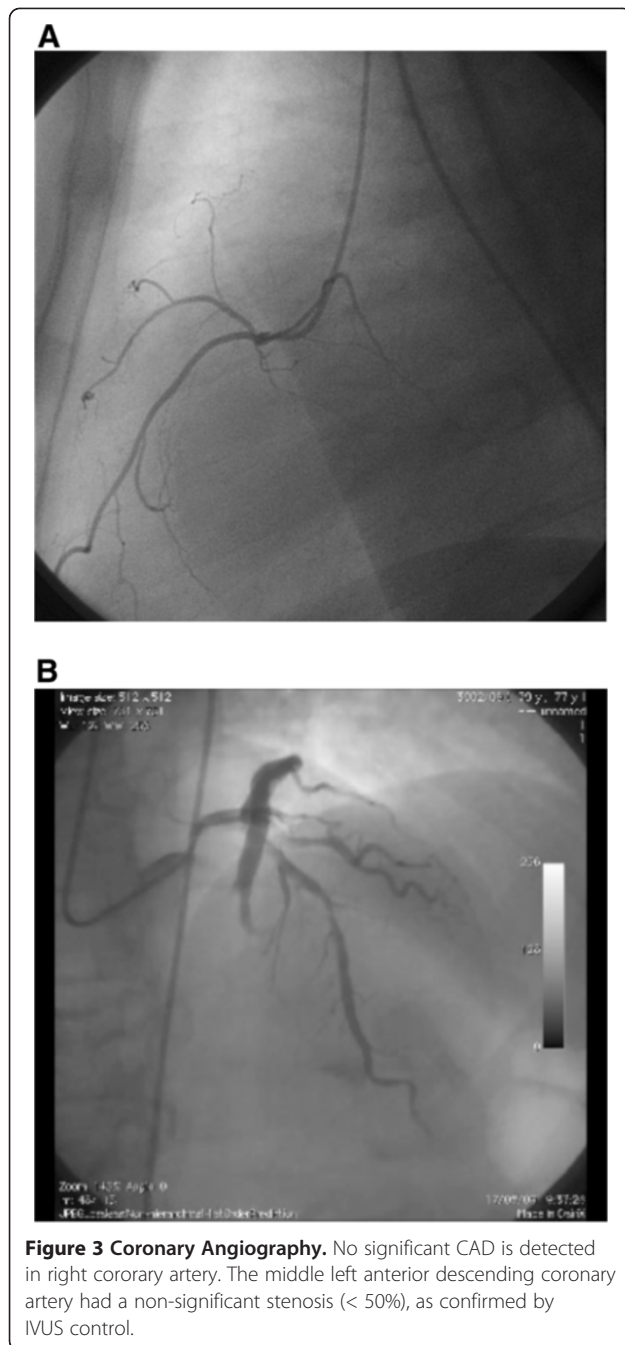
CK-MB level was 8.1 ng/ml (the normal reference value in our laboratory is < 5 ng/ml) only after 6 h from DC shock, and normalized (3.2 ng/ml) within the following 6 h; c) the peak Troponin I level was 0.32 ng/ml (the normal reference value in our laboratory is < 0.08 ng/ml) 6 h after DC shock, and normalized (0.06 ng/ml) 6 h later. No signs of liver or kidney derangement were observed (data not shown).

The patient was discharged 7 days after admission, following the placement of an implantable cardioverter-defibrillator (ICD); the ECG at discharge showed a LBBB with a normal QT interval (QT/QTc = 400/430 msec; Figure 4). After 12 and 24 months of follow-up She has been clinically stable, no shock detected at ICD registration and her QT interval was normal (Figure 5).

Discussion

The occurrence of TdP in our patient after tosylchloramide ingestion can be explained considering that this compound acts as a strong oxidant of methionines and cysteines residues in proteins [7]. The activity of some of the ion channels regulating the duration of the QT interval is, indeed, strongly influenced by oxydation of critical methionine residues in channel proteins. In particular, voltage-dependent inactivation of Na_v channels is significantly slowed down when methionine residues located in the so called IMF domain, which is responsible for

voltage-dependent channel inactivation, are oxydized [8]. Consistently, tosylchloramide, which has a strong preference in oxydizing methionine residues [9], is one of the most powerful oxydants affecting Na_v channel inactivation [9,10] and it has been used as a pharmacological tool to abolish voltage-dependent inactivation in studies aiming to determine its contribution in the activity of specific cardiovascular drugs [11]. Tosylchloramide-induced slowing of Na_v channel inactivation is a quite general phenomenon being observed in the brain, muscle and, importantly, cardiac isoform of these channels [8]. Oxydant-induced impairment of Na_v voltage-dependent inactivation may *per se* explain the appearance of TdP in our patient intoxicated with tosylchloramide since it causes a marked increase in persistent I_{Na} (I_{NaP}) [12,13], the inactivation-resistant Na^+ current which persists in the presence of prolonged membrane depolarization [14]. An increase in I_{NaP} is, indeed, a well documented mechanism of QT prolongation and arrhythmogenesis and a potentially relevant target for treatment and prevention of arrhythmias [15,16]. In addition, an increase in I_{NaP} is considered responsible for arrhythmogenesis in patients affected with the LQT3 syndrome which bear specific mutations in the $\text{Na}_v1.5$ channel gene [17-19]. Confirming the involvement of I_{NaP} in oxydant-induced arrhythmogenesis, the I_{NaP} blocker ranolazine was effective in preventing QT



prolongation and early afterdepolarizations induced by the strong oxidant agent H_2O_2 in cultured guinea pig cardiomyocytes [13]. Therefore, it is tempting to speculate that, in our patient, tosylchloramide exposure recapitulated the pathophysiological mechanism of cardiac arrhythmia in LQT3 patients.

hERG is another oxidation-sensitive ion channel that could have been involved in the genesis of TdP in our patient. hERG is the main K^+ current responsible for rapid repolarization of cardiac myocytes in phase III of

cardiac action potential [20] and its loss of function is one of the best characterized mechanisms of drug-induced or congenital LQT syndrome [21]. Specifically, mutations causing either loss of function or alterations in trafficking of hERG channels are responsible for the LQT2 syndrome [22,23] whereas mutations in MiRP1, an accessory subunit that coassembles with hERG, have been found in LQT6 patients [24]. Intriguingly, by oxidizing critical methionine residues, tosylchloramide causes an almost complete loss of hERG channel activity *in vitro* [25] thus reproducing the effect of drugs or mutations known to cause TdP. Therefore, it is likely that hERG channel blockade could have played a role in the appearance of TdP in our patient.

Finally, it is worth to remind that several oxidants, including tosylchloramide, may also increase the activity of L-type voltage-gated Ca^{2+} channels (VGCC), even though, in this case, the specific involvement of methionine residues has not been demonstrated [26,27]. By increasing Ca^{2+} influx through L-type VGCC, tosylchloramide is expected to prolong the plateau phase of cardiac action potential thus delaying cardiomyocyte repolarization and promoting the appearance of TdP. Intriguingly, an increase in L-type VGCC activity represents the mechanistic base of arrhythmias in LQT8 patients [28-30] bearing the Timothy syndrome mutations which cause an impairment in voltage-dependent $Ca_v1.2$ channel inactivation [31].

Conclusion

Oxidative stress has been proposed as one of the upstream events provoking clinically relevant arrhythmic responses [32] and several drugs used in therapy exert antiarrhythmic effects in part via their antioxidative property [33,34]. Here we suggest that severe arrhythmia may occur in the form of TdP after massive exposure to the oxidizing agent tosylchloramide. In fact, tosylchloramide has a pronounced impact on the activity of some of the ion channels regulating the QT interval. Since our patient exhibited no evidence of QT interval alteration after 12 and 24 months of follow-up, this strongly suggests a causal role of tosylchloramide intoxication for the ECG abnormalities occurred during observation in the ICU. Therefore, a strict electrocardiographic monitoring is advised in patients intoxicated with this compound.

Consent

Written informed consent was obtained from the patient prior to publication of this case report and any accompanying images. A copy of the written consent is available for review by the Series Editor of this journal.

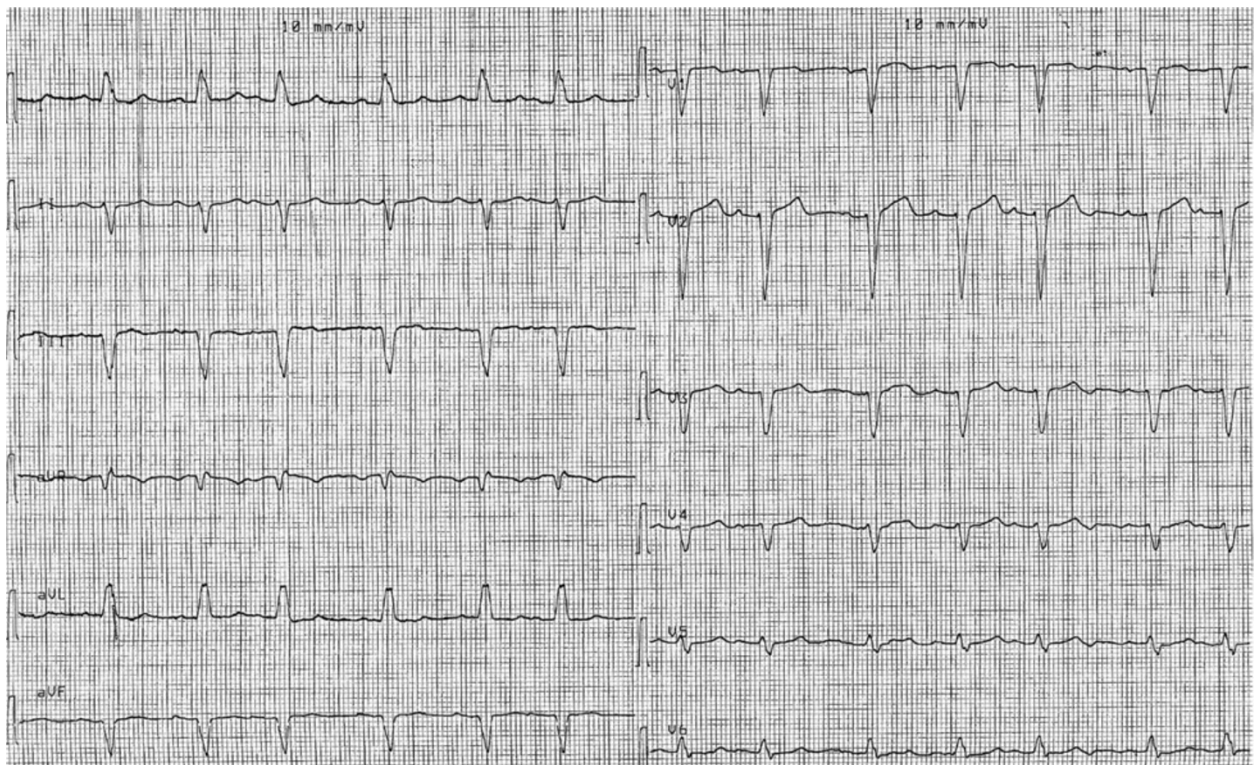


Figure 4 ECG at hospital discharge. QT interval measures 400 msec, the QTc interval 430 msec.

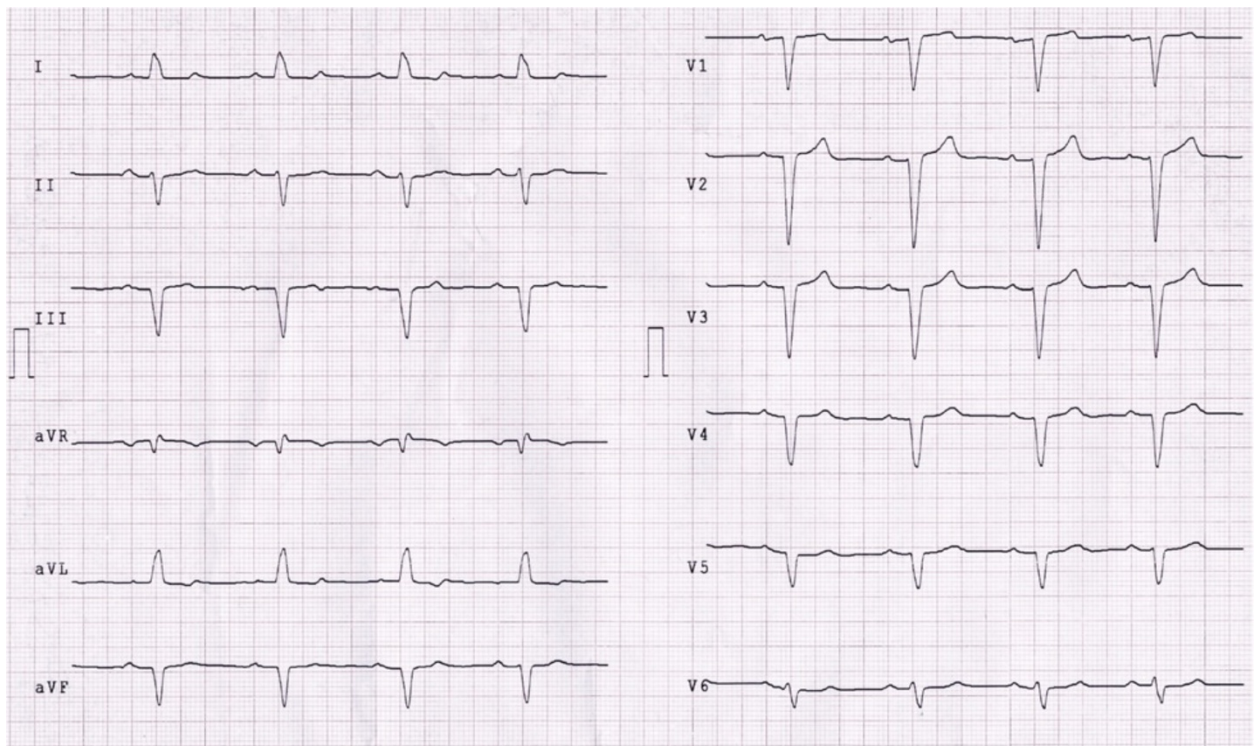


Figure 5 ECG at 1-year follow-up shows stable LBBB and normal QT/QTc interval (405/432 msec).

Competing interest

The authors declare that they have no competing interest.

Authors' contributions

AM identified and managed the case; GPP and SA analyzed the data, conceived of the study and helped to draft the manuscript; VL, MM, AAN and IB performed the literature search and wrote the article. All authors read and approved the final manuscript.

Authors' information

Salvatore Amoroso and Gian Piero Perna equally contributed as senior authors.

Author details

¹Department of "Biomedical Sciences and Public Health, University "Politecnica delle Marche", Ancona, Italy. ²Department of Cardiology, Azienda Ospedaliero-Universitaria "Ospedali Riuniti di Ancona", Ancona, Italy.

Received: 4 September 2012 Accepted: 21 January 2013

Published: 24 January 2013

References

- Blasco A, Joral A, Fuente R, Rodríguez M, García A, Domínguez A: **Bronchial asthma due to sensitization to chloramine T.** *J Investig Allergol Clin Immunol* 1992, **2**:167–170.
- Kujala VM, Reijula KE, Ruotsalainen EM, Heikkinen K: **Occupational asthma due to chloramine-T solution.** *Respir Med* 1995, **89**:693–695.
- Grant WM: *Toxicology of the eye.* Springfield: Charles C. Thomas; 1974.
- Pascuzzi TA, Storrow AB: **Mass casualties from acute inhalation of chloramine gas.** *Mil Med* 1998, **163**:102–104.
- Gonzalez-Castro A, Holanda MS, Canas BS, Morlote JG, Minambres E, Prieto Solis JA: **Myocardial damage after inhalation of chloramines.** *Eur J Emerg Med* 2006, **13**:108–110.
- Thygesen K, Alpert JS, White HD: **Universal definition of myocardial infarction.** *Eur Heart J* 2007, **28**:2525–2538.
- Mihajlovic V, Cascone O, Biscoglio de Jiménez Bonino MJ: **Oxidation of methionine residues in equine growth hormone by Chloramine-T.** *Int J Biochem* 1993, **25**:1189–1193.
- Kassmann M, Hansel A, Leipold E, Birkenbeil J, Lu SQ, Hoshi T, Heinemann SH: **Oxidation of multiple methionine residues impairs rapid sodium channel inactivation.** *Pflugers Arch* 2008, **456**:1085–1095.
- Wang GK: **Irreversible modification of sodium channel inactivation in toad myelinated nerve fibres by the oxidant chloramine-T.** *J Physiol* 1984, **346**:127–141.
- Quiñonez M, DiFranco M, González F: **Involvement of methionine residues in the fast inactivation mechanism of the sodium current from toad skeletal muscle fibers.** *J Membr Biol* 1999, **169**:83–90.
- Nawada T, Tanaka Y, Hisatome I, Sasaki N, Ohtahara A, Kotake H, Mashiba H, Sato R: **Mechanism of inhibition of the sodium current by bepridil in guinea-pig isolated ventricular cells.** *Br J Pharmacol* 1995, **116**:1775–1780.
- Niemann P, Schmidtayer J, Ulbricht W: **Chloramine-T effect on sodium conductance of neuroblastoma cells as studied by whole-cell clamp and single-channel analysis.** *Pflugers Arch* 1991, **418**:129–136.
- Song Y, Shryock JC, Wagner S, Maier LS, Belardinelli L: **Blocking late sodium current reduces hydrogen peroxide-induced arrhythmogenic activity and contractile dysfunction.** *J Pharmacol Exp Ther* 2006, **318**:214–222.
- Maltsev VA, Sabbah HN, Higgins RS, Silverman N, Lesch M, Undrovinas A: **Novel, ultraslow inactivating sodium current in human ventricular cardiomyocytes.** *Circulation* 1998, **98**:2545–2552.
- Hasenfuss G, Maier LS: **Mechanism of action of the new anti-ischemia drug ranolazine.** *Clin Res Cardiol* 2008, **97**:222–226.
- Undrovinas A, Maltsev VA: **Late sodium current is a new therapeutic target to improve contractility and rhythm in failing heart.** *Cardiovasc Hematol Agents Med Chem* 2008, **6**:348–359.
- Bennett PB, Yazawa K, Makita N, George AL Jr: **Molecular mechanism for an inherited cardiac arrhythmia.** *Nature* 1995, **376**:683–685.
- Christé G, Chahine M, Chevalier P, Pásek M: **Changes in action potentials and intracellular ionic homeostasis in a ventricular cell model related to a persistent sodium current in SCN5A mutations underlying LQT3.** *Prog Biophys Mol Biol* 2008, **96**:281–293.
- Tian XL, Yong SL, Wan X, Wu L, Chung MK, Tchou PJ: **Mechanisms by which SCN5A mutation N1325S causes cardiac arrhythmias and sudden death in vivo.** *Cardiovasc Res* 2004, **61**:256–267.
- Tseng GN: **I(Kr): the hERG channel.** *J Mol Cell Cardiol* 2001, **33**:835–849.
- Sanguinetti MC, Jiang C, Curran ME, Keating MT: **A mechanistic link between an inherited and an acquired cardiac arrhythmia: hERG encodes the IKr potassium channel.** *Cell* 1995, **81**:299–307.
- Curran ME, Splawski I, Timothy KW, Vincent GM, Green ED, Keating MT: **A molecular basis for cardiac arrhythmia: hERG mutations cause long QT syndrome.** *Cell* 1995, **80**:795–803.
- Chiang CE, Roden DM: **The long QT syndromes: genetic basis and clinical implications.** *J Am Coll Cardiol* 2000, **36**:1–12.
- Abbott GW, Sesti F, Splawski I, Buck ME, Lehmann MH, Timothy KW, Keating MT, Goldstein SA: **MiRP1 forms IKr potassium channels with hERG and is associated with cardiac arrhythmia.** *Cell* 1999, **97**:175–187.
- Su Z, Limberis J, Martin RL, Xu R, Kolbe K, Heinemann SH, Hoshi T, Cox BF, Gintant GA: **Functional consequences of methionine oxidation of hERG potassium channels.** *Biochem Pharmacol* 2007, **74**:702–711.
- Campbell DL, Stamler JS, Strauss HC: **Redox modulation of L-type calcium channels in ferret ventricular myocytes. Dual mechanism regulation by nitric oxide and S-nitrosothiols.** *J Gen Physiol* 1996, **108**:277–293.
- Yamaoka K, Yakehiro M, Yuki T, Fujii H, Seyama I: **Effect of sulfhydryl reagents on the regulatory system of the L-type Ca channel in frog ventricular myocytes.** *Pflugers Arch* 2000, **440**:207–215.
- Jacobs A, Knight BP, McDonald KT, Burke MC: **Verapamil decreases ventricular tachyarrhythmias in a patient with Timothy syndrome (LQT8).** *Hear Rhythm* 2006, **3**:967–970.
- Splawski I, Timothy KW, Sharpe LM, Decher N, Kumar P, Bloise R, Napolitano C, Schwartz PJ, Joseph RM, Condouris K, Tager-Flusberg H, Priori SG, Sanguinetti MC, Keating MT: **Ca(V)1.2 calcium channel dysfunction causes a multisystem disorder including arrhythmia and autism.** *Cell* 2004, **119**:19–31.
- Splawski I, Timothy KW, Decher N, Kumar P, Sachse FB, Beggs AH, Sanguinetti MC, Keating MT: **Severe arrhythmia disorder caused by cardiac L-type calcium channel mutations.** *Proc Natl Acad Sci USA* 2005, **102**:8089–8096.
- Barrett CF, Tsien RW: **The Timothy syndrome mutation differentially affects voltage- and calcium-dependent inactivation of CaV1.2 L-type calcium channels.** *Proc Natl Acad Sci USA* 2008, **105**:2157–2162.
- Jeong EM, Liu M, Sturdy M, Gao G, Varghese ST, Sovari AA, Dudley SC: **Metabolic stress, reactive oxygen species, and arrhythmia.** *J Mol Cell Cardiol* 2012, **52**:454–463.
- Liu T, Li G: **Antioxidant interventions as novel preventive strategies for postoperative atrial fibrillation.** *Int J Cardiol* 2010, **145**:140–142.
- Naccarelli GV, Lukas MA: **Carvedilol's antiarrhythmic properties: therapeutic implications in patients with left ventricular dysfunction.** *Clin Cardiol* 2005, **28**:165–173.

doi:10.1186/2050-6511-14-8

Cite this article as: Lariccia et al.: Unusual case of severe arrhythmia developed after acute intoxication with tosylchloramide. *BMC Pharmacology and Toxicology* 2013 **14**:8.

Submit your next manuscript to BioMed Central and take full advantage of:

- Convenient online submission
- Thorough peer review
- No space constraints or color figure charges
- Immediate publication on acceptance
- Inclusion in PubMed, CAS, Scopus and Google Scholar
- Research which is freely available for redistribution

Submit your manuscript at
www.biomedcentral.com/submit

